

Vet Rounds for Blue Unit New York City

"Juliet", Elephant, Blue Unit, NYC, 3/31/00

HX - Had a brief bout of loose stool yesterday. Currently better.

PE - BAR, Eating. Normal examination. RF# 1 mild swelling of the interdigital tissues

LB - Blood collected for CBC and Chemistry

Two fecal cultures for Salmonella submitted

TX - Stopped all TB drugs

A: Diet induced diarrhea (change in hay)

P: Monitor

"Kelly", Elephant, Blue Unit, NYC, 3/31/00

HX - Routine exam

PE - BAR. Eating. Normal examination.

A: Normal exam, feet look good

"Bonnie", Elephant, Blue Unit, NYC, 3/31/00

HX - Routine exam

PE - BAR. Eating. Normal examination. Small area of intradigital inflammation between RF# 4/5.

A: Normal exam except mild inflammation

P: Conservative trimming

"Burka", Elephant, Blue Unit, NYC, 3/31/00

HX - Routine exam

PE - Normal examination. Two old wounds on the tail base. Chronic inflammation of the tail tip. RF # 1 and LR # 4 nails have large overgrown lips that need trimming.

TX - Trimmed nails

A: Normal exam

"Minyak", Elephant, Blue Unit, NYC, 3/31/00

HX - Routine exam

PE - BAR, Eating. Normal examination. LF # 2/3 and 3/4 have overgrown cuticles

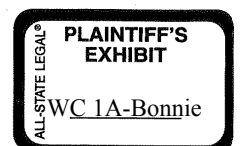
A: Normal exam

"Minnie", Elephant, Blue Unit, NYC, 3/31/00

HX - Routine exam. Recent foot work.

PE - BAR. Eating. Perianial hernia. Chronic NBA LF # 5 (healing)

A: Several Chronic problems



FELD 0021831